



Bilateral profound sensorineural hearing loss after COVID-19 and results after unilateral cochlear implantation.

Hipoacusia neurosensorial bilateral tras COVID-19 y resultados con implante coclear unilateral

Juan Carlos Cisneros Lesser,¹ Laura Rocío Alonso Luján,³ Patricia Acosta Rodríguez,⁴ Evelyn Gross,² María Fernanda Cruz Quiñones⁵

¹ Otorrinolaringólogo, neurotólogo, otólogo y cirujano de base de cráneo, cabeza y cuello.

² Otorrinolaringóloga.

Hospital Ángeles Pedregal, Ciudad de México.

³ Audióloga. Foniatría y Audiología pediátrica, Auditus, Ciudad de México.

⁴ Licenciada en Terapia de Lenguaje, Terapia Auditiva, Instituto Nacional de Rehabilitación Luis Guillermo Ibarra Ibarra, Ciudad de México.

⁵ Médico pasante de servicio social, Instituto Nacional de Cancerología, Ciudad de México.

Correspondence

María Fernanda Cruz Quiñones
mafercrq@gmail.com

Received: September 5, 2024

Accepted: November 11, 2024

This article must be quoted: Cisneros-Lesser JC, Alonso-Luján LR, Acosta-Rodríguez P, Gross E, Cruz-Quiñones MF. Bilateral profound sensorineural hearing loss after COVID-19 and results after unilateral cochlear implantation. *An Orl Mex* 2024; 69 (4): 272-278.

Abstract

BACKGROUND: There are only a few case studies describing the audio-vestibular symptoms related to COVID-19. A previous report shows a prevalence of tinnitus after COVID-19 disease in 14.8%, hearing loss in 7.6%, and vertigo in 7.2%. Most clinical cases worldwide reported a moderate-to-severe sensorineural hearing loss, mainly from high frequencies measured by pure tone audiometry. There is no consensus on a recommended treatment. Some case reports refer clinical improvement with the use of intratympanic steroids, while others advise the combination of intratympanic and systemic steroids.

CLINICAL CASE: A 46-year-old male patient with profound bilateral sensorineural hearing loss after a severe COVID-19 disease, which required in-hospital care for 62 days. Many elements may have participated in the development of his hearing loss. A cochlear implant was placed in the left ear, one year and seven months after being diagnosed with COVID-19.

DOWNLOAD

<https://doi.org/10.24245/aorl.v69i4.10024>

<https://otorrino.org.mx>
<https://nietoeditores.com.mx>

CONCLUSIONS: This case report is the second showing the development of profound bilateral hearing loss after a COVID-19 infection and the results after cochlear implantation; the first one is only described in a letter to the editor.

KEYWORDS: Hearing loss, sensorineural; COVID-19; SARS-CoV-2; Cochlear implant.

Resumen

ANTECEDENTES: Hay pocos estudios de casos que describen síntomas audio-vestibulares relacionados con COVID-19. Un informe anterior muestra una prevalencia de acúfeno después de COVID-19 del 14.8%, pérdida de audición del 7.6% y vértigo del 7.2%. La mayoría de los casos clínicos en todo el mundo informaron pérdida auditiva neurosensorial moderada a grave, principalmente en frecuencias altas, medidas con audiometría de tonos puros. No existe consenso en cuanto al tratamiento recomendado. Algunos informes de casos refieren mejoría clínica con la aplicación de esteroides intratimpánicos, mientras que otros aconsejan la combinación de esteroides intratimpánicos y sistémicos.

CASO CLÍNICO: Paciente masculino de 46 años con hipoacusia neurosensorial bilateral profunda tras padecer un cuadro grave de COVID-19, que requirió atención hospitalaria durante 62 días. Es posible que muchos elementos hayan estado implicados en su pérdida auditiva. Le fue colocado un implante coclear en el oído izquierdo un año siete meses después de haber sido diagnosticado con COVID-19.

CONCLUSIONES: Este informe de caso es el segundo que muestra pérdida auditiva bilateral profunda después de la infección por COVID-19 y los resultados después del implante coclear; el primero solo se describe en una carta al editor.

PALABRAS CLAVE: Pérdida auditiva neurosensorial; COVID-19; SARS-CoV-2; implante coclear.

INTRODUCTION

COVID-19 disease is produced by the SARS-CoV-2 virus infection. It was first identified in December 2019 and took only five months to spread all over the world, with a death toll of more than 6,955,500 people.¹ The clinical presentation of COVID-19 can fluctuate from a mild-symptom context, such as coughing, fever, myalgia, or arthralgia, to a severe-symptom presentation, which may include a severe respiratory syndrome with multiorgan failure.²

The most reported symptoms in the otorhinolaryngological consultation include anosmia, dyspnea, and dysgeusia.³ Few papers describe the audio-vestibular symptoms related to this disease. Ibrahim et. al reported a tinnitus prevalence after COVID-19 infection of 14.8%, 7.6% for hearing loss (without specifying whether it refers to a conductive or sensorineural condition), and 7.2% for vertigo.⁴

Four different theories refer to the mechanisms behind the previously explained symptoms. The first one explains that SARS-CoV-2, as a virus that causes upper-airway infections, can provoke labyrinthitis, sudden sensorineural hearing loss or vestibular neuronitis (unilateral vestibular hypofunction) by direct invasion of the cochlear or vestibular nerves from the middle ear.^{3,5} The second theory says that the SARS-CoV-2 virus causes a microthrombi overproduction that provokes ischemia in the collateral irrigation in the inner ear.^{2,6} The third theory states that antibodies or T-cells activate an immune mediated cross-reaction that misidentifies the antigens inside the inner ear, causing a negative effect in the cochleo-vestibular system. Finally, the fourth theory mentions that these symptoms result from a generalized immunologic reaction identified by an overproduction of pro-inflammatory cytokines.⁴

Most clinical case reports worldwide report mild to severe sensorineural hearing loss, more intense in the high frequencies, as shown in tonal audiometry.⁶ This behavior may relate to a higher presence of angiotensin-converting enzyme 2 (ACE-2) in the external ciliated cells from the basal turn of the cochlea, than in other areas of the inner ear.^{2,7} It has been noted

in other papers, that the S protein of SARS-CoV-2 virus consists of subunits S1 and S2, responsible for the attachment and membrane fusion, respectively. The spike binds to human ACE-2 in the cell membrane through the S1 subunit of the receptor-binding domain.⁸ The ACE-2 acts as a receptor that binds SARS-CoV-2 virus and its high presence in the basal turn of the cochlea makes this site an important landmark for damage by COVID-19.

Other studies give the most importance to otoacoustic emissions when evaluating hearing loss after COVID-19, as for other viral related sensorineural hearing losses.² A recent study by Basoz et al evaluated 23 patients with COVID-19 and 20 normal individuals between the ages of 20-40. TEOAE and distortion product otoacoustic emissions (DPOAE) tests were applied to the groups to evaluate the cochlear function. No significant differences were shown in TEOAE and DPOAE in 1000 Hz, 1400 Hz, 2000 Hz and 2800 Hz values between the 2 groups. However, there was a significant decrease in the 4000 Hz TEOAE value in the patient group [$p = 0.005$]. As described earlier, the high frequency region of the cochlea in the patient group was the most susceptible for damage.⁹

In 2020, Satar¹⁰ recommended new criteria to diagnose sensorineural hearing loss caused by a SARS-CoV-2 infection:

- Positive SARS-CoV-2 PCR test
- Documented hearing loss through the infection period and after four weeks
- Absence of vestibular signs
- No other apparent sensorineural hearing loss causes, such as acoustic trauma, noise exposure, retro-cochlear disease, ototoxic usage, or other reasons

There is no consensus on a recommended treatment for COVID-19 associated tinnitus or hearing loss. Some case studies report improvement using intratympanic steroids as monotherapy, while others suggest a combined therapy that includes systemic and intratympanic steroids.^{11,12}

Until now, only one literature report has shared the experience of a COVID-19 patient diagnosed with secondary hearing loss and receiving a cochlear implant. This case is reflected in a letter written by Chantal Degen, Thomas Lenarz, and Kersting Willenborg to the Mayo Clinic Proceedings editor in 2020.¹³ The letter describes the case of a 60-year-old male with a confirmed COVID-19 diagnosis who presented respiratory insufficiency. After being treated with azithromycin and furosemide within 13 days in the Intensive Care Unit, the patient recovered alert but presented bilateral hearing loss and tinnitus. He was finally diagnosed with left sided profound hearing loss and right sided anacusis. Magnetic resonance showed an inflammatory intracochlear process, which is why a labyrinthitis diagnosis was considered over ototoxicity. Considering the imminent risk for cochlear ossification, the patient received a unilateral implant in the right ear and three intratympanic triamcinolone injections were applied in the left ear. The letter does not mention any clinical outcomes from this treatment. Considering this fact, sharing our experience with a patient showcasing profound bilateral hearing loss after COVID-19 disease and his rehabilitation with a cochlear implant becomes relevant.

CASE REPORT

A 46-year-old male patient with no significant medical history. He developed hearing loss following a COVID-19 infection and required in-hospital care for 62 days. During his hospitalization, he experienced respiratory failure and underwent initial orotracheal intubation, followed by tracheostomy for 30 days. He also had renal failure necessitating dialysis. Throughout his treatment, he received multiple antibiotics, including trimethoprim-sulfamethoxazole, piperacillin-tazobactam, ertapenem, meropenem, linezolid, and ceftazidime-avibactam. When sedation was discontinued, the patient noticed tinnitus and hearing loss, unable to detect even high-intensity sounds.

Brainstem auditory evoked potentials showed a profound high-frequency sensorineural hearing loss. Additionally, a computed tomography scan of the ears revealed signs of mastoiditis and sinusitis.

Comprehensive audiological assessment was conducted at discharge with the following results: Brainstem auditory evoked potentials showed no responses at 100 dB in both ears. Pure tone audiometry demonstrated bilateral profound sensorineural hearing loss with descending audiogram profiles. Speech audiometry revealed no speech discrimination at maximum intensities in both ears. Functional gain, assessed in a free-field environment with FM tones, using a superpower BTE hearing aid, did not cover the language area, especially in the left ear. Speech audiometry with a hearing aid showed no speech discrimination at 65 or 75 dB (**Figure 1**). Tympanometry revealed slightly decreased compliance in the left ear and normal pressures bilaterally. Stapedial reflexes were absent at maximum intensities in both ears, both ipsilateral and contralateral. Magnetic resonance imaging focused on the cerebellopontine angle found no evidence of abnormalities in the inner ear or the VII-VIII neural bundle. No evidence of previous meningitis or encephalitis was shown.

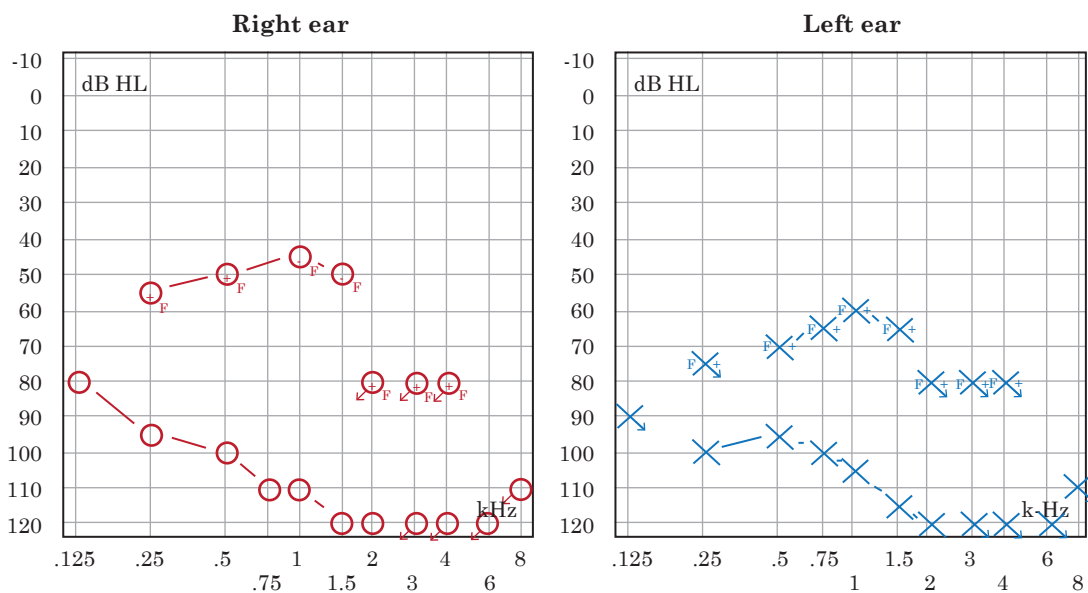


Figure 1

Unaided and aided hearing threshold (preimplantation).

One year and seven months after the onset of COVID-19 symptoms, a cochlear implant was placed in the left ear. It was an Advanced Bionics model (HiRes Ultra) with a HiFocus Slim J electrode, inserted through the round window without complications. Impedances for all 16 electrodes were within the normal range, with neural response imaging (NRI) recorded on all 16 electrodes. Activation was carried out one month later, telemetric measurements were carried out again with impedances in the normal range on the 16 electrodes and neural response imaging on the 16 electrodes.

The clinical response to activation was highly satisfactory, with the patient comprehending short sentences in a closed context on the same day of activation. Bimodal binaural (Naída Q70 with contralateral superpower link hearing aid) adaptation was performed, and one month after activation, the patient identified Ling sounds with occasional confusion between the /s/ and /m/ phonemes but with adequate language discrimination. Audiometry in a free-field environment with the cochlear implant showed a pure tone average of 36.25 dB HL. Speech audiometry with monosyllabic in quiet was 50% at 65 dB HL. Subsequent evolution continued to be satisfactory. Nine months after activation, his pure tone average improved (25 dB HL) and the speech audiometry showed 90% discrimination at 65 dB HL (**Figure 2**). He has returned to his pre-illness occupational activities.

DISCUSSION

In this clinical case, there are multiple factors that could have contributed to the patient's profound bilateral hearing loss. As discussed, the SARS-CoV-2 virus has various mechanisms for causing hearing loss, ranging from neuritis or labyrinthitis, which can occur with many respiratory viruses, to the disruption of microcirculation in the inner ear.^{4,5} The virus has an intrinsic capacity to invade cells expressing ACE-2, such as hair cells in the inner ear.⁸ The patient's acute-stage tomography showed evidence of mastoiditis, which could have facilitated invasion of the inner ear in the form of a viral labyrinthitis. Importantly, the magnetic

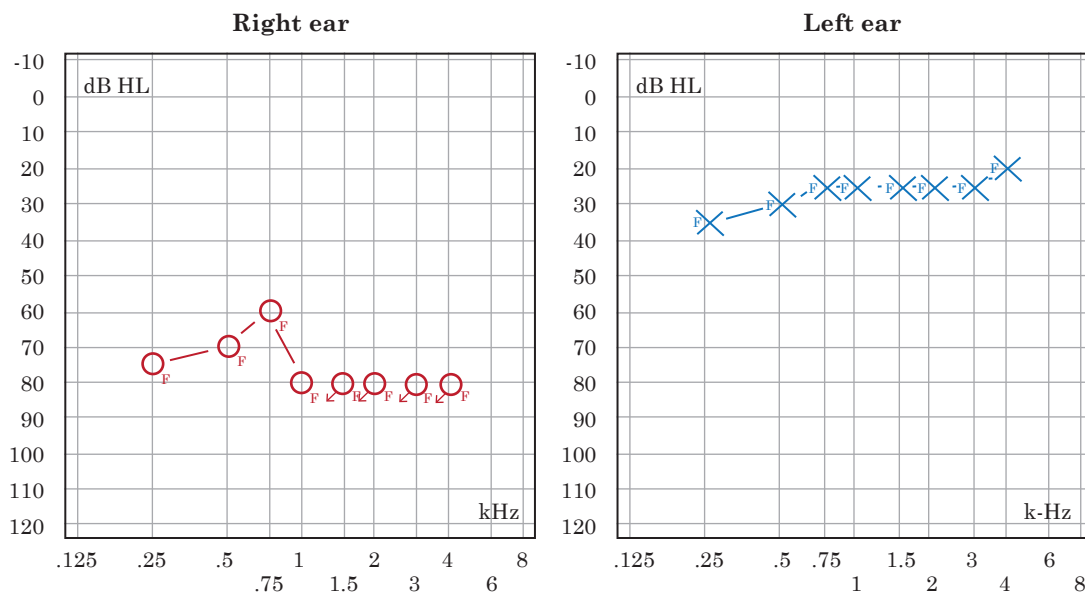


Figure 2

Sound field hearing thresholds, right ear hearing aid monaurally and left ear cochlear implant monaurally.

resonance imaging performed on the patient 1 year and 3 months after discharge, when he was evaluated as a candidate for cochlear implantation, did not show any sequelae from the presumed labyrinthitis, with normal inner ears, and without any evidence of fibrosis or ossification. This finding was confirmed during surgery since an atraumatic soft insertion through the round window, was achieved without any resistance. Impedances observed during neural response telemetry also remained within the normal range.

On the other hand, SARS-CoV-2 is a virus that exhibits clear neurotropism, affecting peripheral nerves and the central nervous system. The olfactory bulb and the nerve endings of the olfactory nerve are commonly affected, but over the past three years, cases of facial paralysis related to COVID-19, sensory-motor alterations in peripheral limbs, and other peripheral neuropathy symptoms have been described.¹⁴ As shown by systematic reviews, multiple auditory-vestibular symptoms can occur in relation to the disease.⁶

Regarding the treatment for hearing loss secondary to COVID-19 disease, there is no established protocol to guide therapeutic decisions. Some authors have prescribed oral steroid courses (usually prednisone) with the rationale that oral steroids are the treatment of choice for sudden sensorineural hearing loss of viral origin. Most studies reported auditory improvement, as confirmed by pure tone audiometry before and after treatment.¹ Other reports conclude that dual therapy, combining oral and intratympanic steroids, demonstrates audiometric improvement.¹¹ However, in our case report, the patient underwent cochlear implantation as treatment more than a year after his hearing loss. As stated before, to date there is only one reported case in the literature of a patient who received a cochlear implant after COVID-19 labyrinthitis due to the risk of cochlear ossification, but long-term results were not reported.¹²

Hypoxia is a factor to consider in our patient, even though he was promptly treated for respiratory failure with intubation and eventually tracheostomy, he had low oxygen saturation levels for several weeks that could have caused hypoxia-related damage to the inner ear or central auditory pathways. Nevertheless, the excellent clinical response shown by the patient from the day of activation suggests an absence of central auditory processing disorders, which would be significant in cases of cerebral hypoxia.

The reported patient received multiple antibiotics such as trimethoprim-sulfamethoxazole, piperacillin-tazobactam, ertapenem, meropenem, linezolid, and ceftazidime-avibactam. None of the aforementioned antibiotics has a significant ototoxic effect, so we do not consider them to be a major factor contributing to the hearing loss.

Finally, it should be noted that our patient experienced renal failure requiring hemodialysis and the use of diuretics during his stay in the intensive care unit, particularly furosemide, which has a probable ototoxic effect.

CONCLUSIONS

There are more and more reports of sensorineural hearing loss related to COVID-19 disease, and many studies have now documented the pathophysiological mechanisms for this connection. Most studies show patients having high frequency moderate to severe sensorineural hearing losses and there are very few studies showing patients with profound hearing loss after COVID-19. In this case report many could be the causes for the exhibited bilateral profound hearing loss as discussed earlier, being hypoxia, the use of diuretics and the viral

infection by SARS-CoV-2 (considering COVID-19-associated coagulopathy and/or direct viral invasion of the labyrinth or cochlear nerve) the most notable. An excellent response to cochlear implantation was observed after more than a year of the hearing-loss. This is only the second report in the literature that shares the experience of a COVID-19 patient diagnosed with secondary hearing loss and receiving a cochlear implant.

REFERENCES

1. Chern A, Famuyide AO, Moonis G, Lalwani AK. Bilateral sudden sensorineural hearing loss and intralabyrinthine hemorrhage in a patient with COVID-19. *Otol Neurotol* 2021; 42 (1): e10-4. doi: 10.1097/MAO.0000000000002860
2. Swain SK. Hearing loss, tinnitus and vertigo among pediatric patients with COVID-19 infections: a review. *Int J Contemp Pediatrics* 2021; 8 (10): 1756. <https://doi.org/10.18203/2349-3291.ijcp20213744>
3. Pokharel S, Tamang S, Pokharel S, Mahaseth RK. Sudden sensorineural hearing loss in a post-COVID-19 patient. *Clin Case Rep* 2021; 9 (10). doi: 10.1002/ccr3.4956
4. Almufarrij I, Munro KJ. One year on: an updated systematic review of SARS-CoV-2, COVID-19 and audio-vestibular symptoms. *Int J Audiol* 2021; 60: 935-45. doi: 10.1080/14992027.2021.189679
5. Karimi-Galougahi M, Naeini AS, Raad N, Mikaniki N, Ghorbani J. Vertigo and hearing loss during the covid-19 pandemic – is there an association? *Acta Otorhinolaryngol Ital* 2020; 40: 463-5. doi: 10.14639/0392-100X-N0820
6. Umashankar A, Prakash P, Prabhu P. Sudden sensorineural hearing loss post coronavirus disease: A systematic review of case reports. *Indian J Otolaryngol Head Neck Surg* 2022; 74: 3028-35. doi: 10.1007/s12070-021-02756-w
7. Chirakkal P, Al Hail AN, Zada N, Vijayakumar DS. COVID-19 and tinnitus. *Ear Nose Throat J* 2021; 100 (2_suppl): 160S-162S. doi: 10.1177/0145561320974849
8. Beyerstedt S, Barbosa Casaro E, Bevilaqua Rangel É. COVID-19: angiotensin-converting enzyme 2 (ACE2) expression and tissue susceptibility to SARS-CoV-2 infection. *Eur J Clin Microbiol Infect Dis* 2021; 40: 905-919. <https://doi.org/10.1007/s10096-020-04138-6>
9. Basoz M, Tas N, Gedik O, Ozdemir S, Aksoy F. Transient otoacoustic emissions with contralateral suppression findings in COVID-19 patients. *Egypt J Otolaryngol* 2022; 38 (1). doi: 10.1186/s43163-022-00231-z
10. Satar B. Criteria for establishing an association between Covid-19 and hearing loss. *Am J Otolaryngol Head Neck Med Surg* 2020; 41. doi: 10.1016/j.amjoto.2020.102658
11. Abdel Rhman S, Abdel Wahid A. COVID-19 and sudden sensorineural hearing loss, a case report. *Otolaryngol Case Rep* 2020; 16. doi: 10.1016/j.xocr.2020.100198
12. Koumpa FS, Forde CT, Manjaly JG. Sudden irreversible hearing loss post COVID-19. *BMJ Case Rep* 2020; 13 (11). doi: 10.1136/bcr-2020-238419
13. C. Degen, T. Lenarz, K. Willenborg. Acute profound sensorineural hearing loss after COVID-19 pneumonia. *Mayo Clin Proc* 2020; 95 (8): 1801-1803. doi: 10.1016/j.mayocp.2020.05.034
14. Khurshid A, Khurshid M, Sohail A, Raza IM, et al. Facial palsy as a manifestation of COVID-19: A systematic review of cases. *Health Sci Rep* 2022; 5 (6). doi: 10.1002/hsr2.887